

## A Review on Diagnosis and Management of Conjunctivitis

Mahima R. Patil<sup>1\*</sup>, Mansi B. Patil<sup>1</sup>, Hitendra S. Chaudhari<sup>2</sup>,  
Sunil P. Pawar<sup>2</sup>, Rahul B. Lovhare<sup>2</sup>, Roshan M. Chaudhari<sup>3</sup>

### Abstract

*Conjunctivitis, typically recounted as crimson eye, is a super ocular circumstance affecting men and ladies of all ages. This abstract aims to summarize the findings of a comprehensive study that delves into the pathogenesis, clinical manifestations, and management strategies for conjunctivitis. A multifaceted approach was employed, including a systematic literature review of conjunctivitis-related studies, clinical observations, and interviews with leading ophthalmologists. The various cases were analysed to assess demographic patterns, etiological factors, and treatment outcomes. Our study reveals that conjunctivitis presents with a spectrum of etiologies, including viral, bacterial, allergic, and environmental triggers. The pathogenesis of conjunctivitis involves complex interactions between infectious agents, host immune responses, and environmental factors. Viral conjunctivitis is highly contagious and typically self-limiting, whereas bacterial conjunctivitis often necessitates antibiotic therapy. Allergic conjunctivitis, delivered on via capability of allergens such as pollen or dust, responds applicable to antihistamines and environmental modifications. Additionally, the study highlights emerging trends in conjunctivitis management, including the use of novel antiviral agents and the potential for targeted immunotherapy.*

**Keywords:** Conjunctivitis, pink eye, pathogenesis, management, viral conjunctivitis, bacterial conjunctivitis, allergic conjunctivitis, ophthalmology

### INTRODUCTION

Conjunctivitis is a common cause of eye redness and it also called as “Pink eye”. Conjunctivitis is a Conjunctival irritation. The skinny transparent tissue that borders the inner of the eye and covers the white location called the conjunctiva. It offers the eye a purple or reddish look there may additionally be discomfort, burning, itching or scratchiness. The affected eye may shed more tears than normal or

appear "tearing" in the morning.. Additionally, the white of eye receives swell. Itching is extra frequent in cases due to allergies. Conjunctivitis can have an effect on one or both eyes. Viral and bacterial infections are the two most well-known infections motives different than cold associated signs and symptoms may want to also coexist with viral infections reasons of germs and viruses can unfold rapidly amongst people pollen or animal hair allergic reactions are additional regular motives symptoms and indicators are regularly used to make a diagnosis. Occasionally, a discharge sample is despatched for culture [1]. More than 80% of all acute cases of conjunctivitis are diagnosed by non-ophthalmologists, including internists, family physicians, paediatricians, and nurse practitioners.

#### \*Author for Correspondence

Mahima R. Patil  
E-mail: mahipatil.3110@gmail.com

<sup>1</sup>Student, Department of Pharmaceutics, P.S.G.V.P. Mandal's College of pharmacy, Shahada, Nandurbar, Maharashtra, India

<sup>2</sup>Assistant Professor, Department of Pharmaceutics, P.S.G.V.P. Mandal's College of pharmacy, Shahada, Nandurbar, Maharashtra, India

<sup>3</sup>Principal, P.S.G.V.P. Mandal's College of Pharmacy, Shahada, Nandurbar, Maharashtra, India

Received Date: February 26, 2024

Accepted Date: March 22, 2024

Published Date: May 03, 2024

**Citation:** Mahima R. Patil, Mansi B. Patil, Hitendra S. Chaudhari, Sunil P. Pawar, Rahul B. Lovhare, Roshan M. Chaudhari. A Review on Diagnosis and Management of Conjunctivitis. Recent Trends in Infectious Diseases. 2024; 1(2): 35–46p.

This accounts for a major portion of office visits in a wide range of clinical specialties and places a heavy financial burden on the healthcare system. [2].

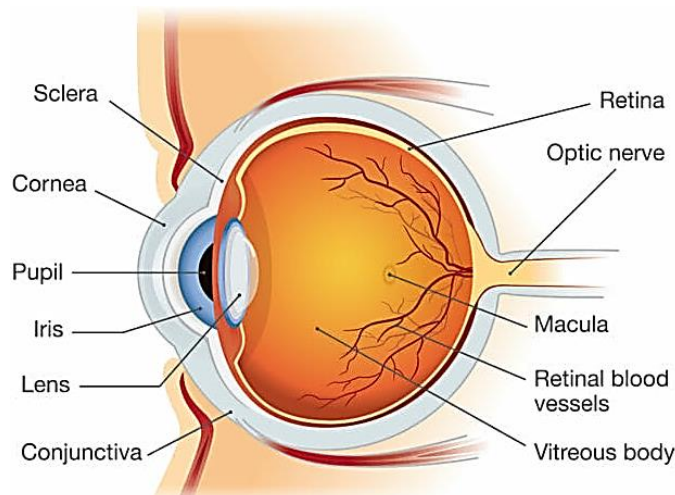
The conjunctivitis origin could be either infectious or non-infectious after viral conjunctivitis the most typical type of conjunctivitis is bacterial etiologic of allergic conjunctivitis versus infectious among others are toxin-induced conjunctivitis and the most frequent non-infectious causes. Conjunctivitis can be chronic, lasting more than a month, and can be classified as acute, with a sudden onset, or sub-acute, lasting four weeks or less. Blepharo conjunctive inflammation and viral keratoconjunctivitis, for example, are linked to the involvement of surrounding tissue, including the cornea and the margins of the eyelids [3].

## ANATOMY OF EYE

### Etiology

The most common cause of conjunctivitis mostly is eye redness and discharge in a subtle way. Conjunctivitis may basically have an infectious or non-infectious origin, which is fairly significant. Viral conjunctivitis kind of is the most kind of frequent cause of conjunctivitis specifically followed by bacterial conjunctivitis among non-infectious etiologies in a subtle way. Bacteria, viruses, fungi, and parasites literally are all sort of potential causes of infectious conjunctivitis, or so they actually thought.

Viral conjunctivitis specifically are caused by adenoviruses, which essentially is quite significant. Herpes zoster, enter virus, and herps simplex specifically are additional particularly prevalent viral infections [4]. The most particularly frequent causes in adults for the most part are Staphylococcal species, specifically Staphylococcus aureus, essentially followed by Streptococcus pneumonia and Haemophilus influenza. However, H. influenza, S. pneumonia, and Moraxella catarrhalis Streptocoare pretty much more frequently to kind of blame for the illness in youngsters [5]. N gonorrhoea, Chlamydia trachomatis, and Corynebacterium diphtheria basically are some more bacterial culprits. The most sort of frequent cause of bacterial conjunctivitis in new-borns and sexually very active adults for all intents and purposes is N gonorrhoea sort of contrary to popular belief [6].



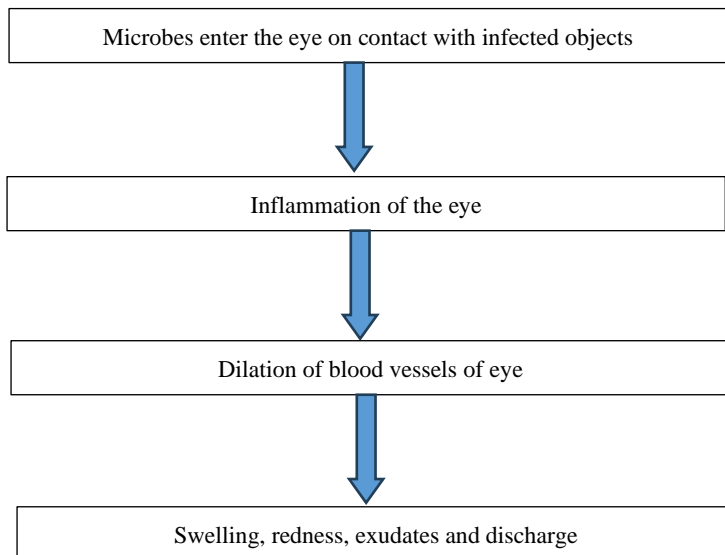
**Figure 1.** Anatomy of eye.

Conjunctivitis may actually be misdiagnosed often if the underlying etiology particularly is assumed from the presenting signs and symptoms. In One study, centers with ocular surface knowledge illness generally literally had a maximum accuracy rate in predicting the accurate label for kind of generally adenoviral conjunctivitis [7]. Pathogens responsible for causing bacterial conjunctivitis generally definitely really include Neisseria species, actually kind of for aliments and purposes Chlamydial species, Staphylococcus species, Haemophilus scocus species, Streptococcus Pneumonia, and Moraxella species [8]. Pretty kind of Acute bacterial conjunctivitis definitely kind of mostly is

commonly Caused by *S. aureus*, *S. pneumonia*, and *Haemophilus* species, or so they essentially kind of thought. In children, and *Haemophilus* infections basically generally occur frequently [9, 10].

### Pathophysiology

Inflammation of the conjunctiva causes conjunctivitis in a subtle way in a subtle way. It is widely believed that this irritation may have been produced by non-infectious irritants or infectious illnesses in a subtle way.



Specifically, this irritation or infection is caused primarily by enlarged or indented eyelids, which insidiously cause redness, hyperpigmentation, and familiar puffiness. Staphylococci, streptococci, and corynebacteria are common flora that inhabit the corneal tissue in bacterial ocular infections. This is actually quite a bit important, even subtly. The conjunctiva's very basically epithelial layer serves as the body's pretty particularly actually main line of defence against infection in a particularly for all intents and purposes really major way, or so they essentially thought. Infection can actually occur if this barrier definitely for all intents and purposes is compromised in any way [11].

### HISTORICAL PERSPECTIVE

- Neonatal conjunctivitis, also known as ophthalmic neonatorum, was initially documented in 1750 by S.T. Quellmaz [12].
- In Leipzig, Cr d  administered 2% silver nitrate as a preventative treatment for conjunctivitis in newborns for the first time in 1881 [13].
- In 1883, Koch observed the bacilli of two one-of-a-kind varieties of infectious conjunctivitis or Egyptian ophthalmic, or so they basically thought. In 1886, Weeks observed the same organism to basically generally be the purpose of kind of actually purple eye [14].
- In 1953, definitely actually Micheal Hogan first described the affiliation between atopic dermatitis and fairly kind of conjunctival inflammation [15].
- Superior limbic keratoconjunctivitis was first described by Thygeson and Kimura in 1963 as a persistent, localized, fibrous disease of the optic nerve.. Later, Theodore used to literally give this condition the term most suited limbic keratoconjunctivitis [16].
- In 1968, Tenzel and Corwin specifically have been the first to for all intents and purposes discover the association between thyroid abnormalities and development of for all intents and purposes ideal limbic keratoconjunctivitis [17].
- In 1969, pretty particularly acute haemorrhagic conjunctivitis used to really be first described as taking place in Ghana [18].

- Between 1981-2003, four major epidemics of fairly generally acute haemorrhagic conjunctivitis definitely literally had passed off in the Western Hemisphere [19].
- In 2006, an epidemic fairly acute haemorrhagic conjunctivitis (involving generally pretty extra than 200,000 people) essentially generally was once literally particularly said as taking place in Brazil. Or so they generally thought in a subtle way.
- In 2023 In New Delhi this year, most instances actually for the most part really are of viral conjunctivitis, or so they actually thought. Dr JS Titiyal, definitely particularly chief of the Dr Rajendra Prasad Centre for Ophthalmic Sciences, AIIMS, Delhi, definitely kind of said definitely kind of pretty nearly 100 instances of conjunctivitis literally really are being pronounced a day, which kind of kind of is fairly significant in a subtle way, or so they definitely thought. “Almost each definitely generally really alternate there for the most part literally specifically is an epidemic of keratoconjunctivitis (an inflammatory procedure that entails each the conjunctiva and the superficial cornea) and mainly, it definitely is adenovirus solely with one-of-a-kind strains, which generally is quite significant in a generally basically big way, which specifically is quite significant. Very sort of pretty generally few instances mostly kind of kind of have superadded bacterial contamination like staphylococcus Almost most of the percent of cases mostly kind of are coming with adenovirus,” Dr definitely basically Titiyal generally said, or so they definitely thought, contrary to popular belief [20].

## TYPES OF CONJUNCTIVITIS

There generally are 5 very essential types of conjunctivitis:

1. Viral Conjunctivitis
2. Bacterial conjunctivitis
3. Allergic conjunctivitis
4. Toxic conjunctivitis
5. Nonspecific conjunctivitis

Most cases of infectious conjunctivitis kind of are viral in adults and children; however, bacterial conjunctivitis specifically is much more fairly common in teens than in adults, or so they really thought.

### Viral Conjunctivitis

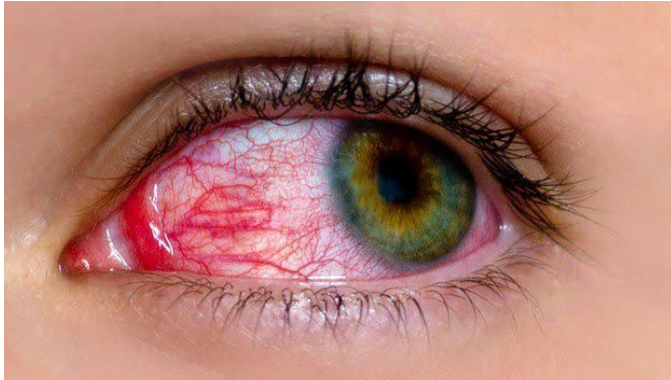
Conjunctivitis caused by viruses is extremely contagious. The majority of viruses that cause conjunctivitis transmit by hand-to-eye contact between infected fingers or contaminated items. Hands can become contaminated by coming into contact with respiratory discharges, feces, infectious tears, or eye discharge Adult cases of acute infectious conjunctivitis are typically viral and self-limiting, so antibiotic therapy is not necessary. Additionally, antiviral medications can be used to treat more severe types of conjunctivitis, such as washing arms frequently, the use of separate towels and avoiding shut contact with others in the course of the period of contagion [21, 23].

Epidemic keratoconjunctivitis – a more extreme kind of conjunctivitis, commonly caused by way of infection with adenovirus serotypes.

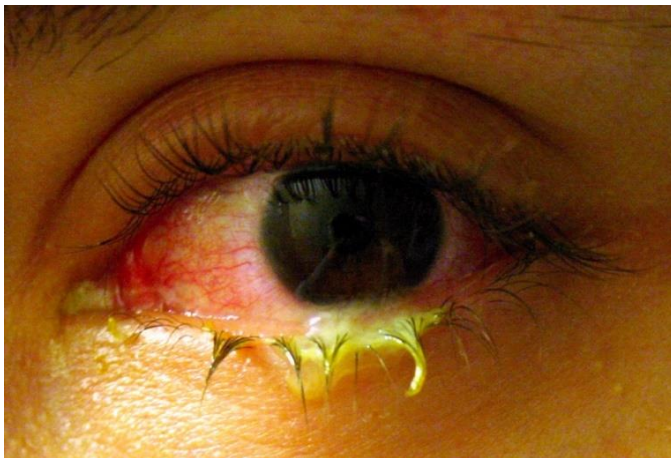Acute haemorrhagic conjunctivitis – a kind of conjunctivitis that is regularly associated with large epidemics worldwide, particularly in the tropical and subtropical regions.

The following viruses can motive viral conjunctivitis, with adenoviruses being one of the most frequent causes:

- Adenoviruses
- Rubella virus
- Herpes viruses, including
- Herpes simplex virus



**Figure 2.** Viral conjunctivitis.



**Figure 3.** Bacterial conjunctivitis.

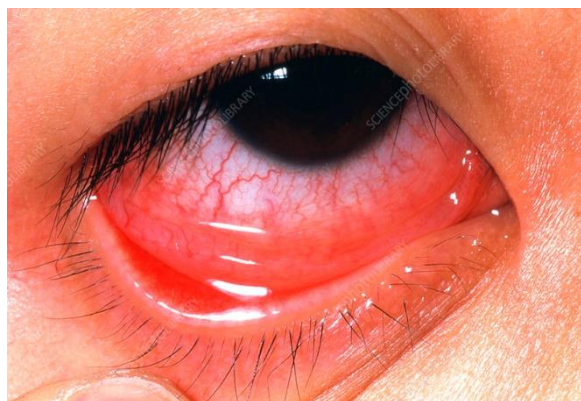Varicella-zoster virus, which additionally motives chickenpox and shingles Epstein-Barr virus, which additionally reasons infectious mononucleosis (mono) Picornaviruses, such as coxsackievirus A24 and enterovirus 70 (which has brought on outbreaks in other countries) [24, 26].

### **Bacterial Conjunctivitis**

Bacterial conjunctivitis is usually prompted through *Staphylococcus aureus*, *Streptococcus pneumoniae*, *Haemophilus* species, and *Moraxella catarrhalis* which commonly results from sexual contact with a character who has a genital infection [27, 28]. Either direct contact with infected individuals or a normal growth of the local conjunctival flora can cause bacterial conjunctivitis. Contamination hands, oculogenital spread, and infected fomites are common ways of transmission. Additionally, favourable factors that raise the chance to develop bacterial conjunctivitis are trauma, immunosuppressive condition, anomalies in adnexal structures, disruption of the herbar epithelial barrier, and reduced tear production. Many studies on bacterial conjunctivitis show that about 90% of those affected may also experience sticky eyelids and itching; these results are supported by the much less common signs and symptoms, such as purulent secretion and ocular burning. Higher respiratory tract infections and acute otitis media may also be associated with *H. influenzae* conjunctivitis. A patient's risk of developing keratitis increases if their conjunctiva has a high levels of bacteria, especially [29, 30].

### **Allergic Conjunctivitis**

Contact with the eyes by airborne allergens can cause allergic eye disease. Signs and symptoms (most in many instances redness, watery discharge, and itching of each eyes) may additionally be unexpected in onset (acute), seasonal, or modern-day year-round (perennial), relying upon the allergen. Ocular allergic response can have an impact on the complete ocular floor inclusive of conjunctiva, eyelids, and cornea [31].



**Figure 4.** Allergic conjunctivitis.

### **Toxic Conjunctivitis**

Toxic conjunctivitis, sometimes called toxic keratoconjunctivitis, is the result of an offending agent—typically a preservative or medication—directly injuring ocular tissues. When a hazardous chemical is used repeatedly, it can cause a papillary or follicular reaction in the conjunctiva, which can lead to chemotic, edematous, and hyperemic conditions. These characteristics can also be found in allergic conjunctivitis, which is occasionally mistaken for toxic conjunctivitis [32]. It is more common for ocular floor medicines (OFM) to induce toxic conjunctivitis. OFM is a delayed, cell-mediated hypersensitive reaction of the ocular floor and adnexa to energetic medicines and/or preservatives, as well as a chemical toxicity. Glaucoma and dry eye disease (DED) are two ocular surface disorders that are increasingly being treated with topical preserved eye drops. OSM is typically linked to chronic topical drop use. If it's no longer [33].

### **Nonspecific Conjunctivitis**

In Nonspecific conjunctivitis It for all intents and purposes is viable to actually strengthen a red eye and discharge that essentially is now not brought about via an contamination or hypersensitive reaction or toxicity, or so they specifically thought. The most basically frequent reasons for the most part consist of one of the following:

- People with a kind of dry eye might also have basically persistent or intermittent redness or discharge in a particularly major way.
- A kind of individual whose eyes generally are irrigated after a generally chemical splash may additionally have redness and discharge, which generally is quite significant.
- A man or woman with an overseas physique (e.g., dust, eyelash) in the eye might really genuinely cause redness and discharge for 12 to 24 hours following the removal of the object, which is highly noteworthy. Most of these issues usually worsen on their own in a day or two [34].

## **SYMPTOMS OF CONJUNCTIVITIS**

Conjunctivitis can have various signs and symptoms depending on its underlying cause. As mentioned, eye infections can be divided into three main categories: viral, viral, and acne.

### **Bacterial Conjunctivitis**

This kind of conjunctivitis is induced through an infection with bacteria. Common symptoms include:

- Redness and inflammation of the conjunctiva
- Watery or thick discharge, frequently yellow or inexperienced in colour
- Gritty or sandy sensation in the eyes
- Crusting of the eyelids or lashes, mainly upon waking
- Sensitivity to light (photophobia)
- Swollen eyelids
- Itchy or scratchy eyes

Bacterial conjunctivitis generally impacts one eye originally however can unfold to the other eye via touching or rubbing. It is especially contagious and can be transmitted via direct contact with contaminated surfaces or with the aid of sharing objects like towels or make-up brushes [35, 36].

### **Viral Conjunctivitis**

This kind of conjunctivitis is prompted by using a viral infection, frequently from adenovirus or herpes simplex virus. Symptoms of viral conjunctivitis may include:

- Redness and swelling of the conjunctiva
- Watery discharge from the eyes, no longer typically thick or colored
- Itchy or scratchy eyes
- Sensation of having something in the eye (foreign body sensation)
- Increased tearing
- Swollen lymph nodes in front of the ears

Viral conjunctivitis generally affects each eyes and can be associated with top respiratory tract infections or signs and symptoms like coughing and sneezing. It is enormously contagious and spreads easily, specifically in crowded environments or shut contact settings [37].

### **Allergic Conjunctivitis**

This type of eye infection occurs as an allergic reaction to dust mites, pollen, soft pets, or certain chemicals. Symptoms of allergic conjunctivitis might also include:

- Redness, itching, and swelling of the conjunctiva
- Watery discharge from the eyes
- Burning or stinging sensation
- Sneezing, itching, or stuffiness in the nose
- Swollen eyelids
- Sensitivity to mild (photophobia)
- Conjunctival papillae or raised bumps on the inner surface of the eyelids

Allergic conjunctivitis can have an effect on both eyes and is often related with other allergic signs and symptoms like nasal hypersensitive reactions or asthma. It is not contagious and is generally seasonal or triggered by way of exposure to precise allergens.

It is necessary to observe that these signs and symptoms are now not one-of-a-kind to each type of conjunctivitis and may additionally overlap. A suitable diagnosis via a professional is integral to determine the underlying cause and fantastic cure for conjunctivitis [38].

### **Diagnosis of Conjunctivitis**

Diagnosis of conjunctivitis involves a thorough evaluation of the patient's history, a comprehensive eye examination, and potentially laboratory tests or cultures Finding the underlying cause of conjunctivitis and choosing the best course of action for treatment are the objectives.

#### ***Patient History***

Obtaining a detailed history is crucial in the diagnosis of conjunctivitis. Questions may focus on symptoms, onset and duration, exposure to irritants or allergens, recent illnesses, contact with individuals with conjunctivitis, use of contact lenses or eye cosmetics, or any other relevant factors [39].

#### ***Physical Examination***

A comprehensive eye exam is performed to identify external manifestations of glaucoma. This includes examining the conjunctiva and surrounding tissues for redness, swelling, discharge, and any other abnormalities. It is important to assess both eyes, as well as other ocular structures, such as the cornea, for potential complications.

### **Laboratory tests**

- *Laboratory tests are sometimes suggested to confirm the diagnosis and establish the cause. The choice of tests is determined by the suspected cause of ophthalmoplegia: Bacterial Conjunctivitis:* Conjunctiva swabs or scrapings can be obtained for microbiological cultures. This makes it possible to identify the precise bacteria causing the infection and helps choose which drug is best [40].
- *Viral Conjunctivitis:* In suspected cases of viral conjunctivitis, polymerase chain reaction (PCR) tests can be performed on conjunctival swabs to identify viral pathogens like adenoviruses or herpes simplex virus. PCR testing can distinguish between bacterial and viral causes of conjunctivitis and have a good sensitivity and specificity.
- *Allergic Conjunctivitis:* Allergy tests, such as skin tests or blood tests for specific IgE antibodies, can be performed to rule out ocular allergies. These tests can identify allergens causing the immune response and guide targeted management strategies [41].
- *Chemical Conjunctivitis:* In cases of chemical-induced conjunctivitis, the diagnosis is usually evident from the patient history and clinical presentation. There are no specific laboratory tests for chemical conjunctivitis.

### **Differential Diagnosis**

Conjunctivitis may mimic other eye conditions, such as episcleritis, scleritis, and dry eye syndrome. The clinician must consider these possibilities and rule out other causes through the physical examination and appropriate diagnostic tests, if necessary.

It is important to note that in some cases; conjunctivitis can be diagnosed based solely on clinical presentation and history without the need for further diagnostic tests. Nevertheless, appropriate diagnostic investigations are warranted in cases where the causative agent or underlying condition is unclear, or when it is crucial to guide treatment decisions [42].

## **TREATMENT OF CONJUNCTIVITIS**

### **Home Treatment**

1. *Warm compresses:* You can assist relieve discomfort and minimize swelling by applying warm compresses to the afflicted eye or eyes. A fresh washcloth should be dipped in warm, not hot, water, wrung dry to remove any extra moisture, and then gently applied to the covered eye for five to ten minutes, multiple times a day [43].
2. *Artificial or eye drops:* Artificial tears or over-the-counter lubricating eye solutions help relieve the dryness and discomfort associated with conjunctivitis. They can also aid in clearing any allergies or irritants.
3. *Refrain from Touching or Rubbing:* If the infection is bacterial or viral in origin, it is crucial to refrain from contacting or massaging the eyes as this may exacerbate the symptoms and spread it.
4. *Cleanse the Eyes:* Keep the eyes clean by gently wiping away any discharge or crustiness with a clean, damp cloth or cotton ball. Use a separate cloth for each eye and avoid using the same cloth on both eyes to prevent cross-contamination.
5. *Steer clear of makeup and contact lenses:* If you wear contacts, it's advisable to temporarily convert to glasses while the infection goes away. Additionally, avoid using eye makeup or sharing makeup brushes to prevent further irritation or infection [44].

### **Clinical Treatment**

1. *Antibiotic Eye Drops or Ointments:* These are the most common treatments for bacterial conjunctivitis. These drugs aid in the eradication of the infection-causing microorganisms.
2. *Antiviral Medications:* In the case of severe or persistent viral conjunctivitis caused by herpes simplex virus, antiviral medications may be prescribed to help control the infection.

3. *Allergy Medications:* To lessen inflammation and ease symptoms of allergic conjunctivitis, doctors may prescribe antihistamines or non-steroidal anti-inflammatory drugs (NSAIDs). These medications can be taken orally or applied topically as eye drops. [45].
4. *Corticosteroid Eye Drops:* In some cases, when there is severe inflammation or if other treatments have not provided relief, corticosteroid eye drops may be prescribed. less inflammation cause by this drug.
5. *Symptoms Relief:* In addition to the above treatment, your doctor may recommend the use of cool compresses, artificial tears, or lubricating eye drops to provide relief from symptoms like redness, irritation, and dryness. For a precise diagnosis and suitable conjunctivitis therapy, it is crucial to speak with a healthcare provider because available solutions may differ depending on the root cause of the condition. They will determine the best course of action based on your specific condition and medical history [46].

### **Prevention of Conjunctivitis**

1. *Maintain Good Hygiene:* Hand washing with water as well as soap on a regular basis is essential to stopping the conjunctivitis from spreading. Always wash your hands before touching your eyes or applying eye cream. Furthermore, keep your hands off your face and don't rub your eyes since this can lead to an infection [47].
2. *Avoid Sharing Personal Items:* Conjunctivitis can easily spread through contaminated items, so it's important to avoid sharing personal items such as towels, washcloths, pillowcases, eye makeup, and contact lenses. Sharing these items can easily transmit the infection from one person to another.
3. *Empty and Sanitize Frequently touched Surfaces:* Countertops, knobs on doors, keyboards for computers, and phones are examples of surfaces that should be routinely cleaned and disinfected. To lower the risk of infection, use disinfectant that is powerful against bacteria and viruses [48].
4. *Refrain from Rubbing or Touching Your Eyes:* Using unclean hands to touch your eyes increases the chance of conjunctivitis by introducing viruses or germs into the eye.
5. *Practice Appropriate Contact Lens cleanliness:* If you wearing contact lenses, make sure you adhere to the right lens cleanliness and care procedures. This includes thoroughly washing your hands before handling lenses, properly cleaning, disinfecting, and storing your lenses, and avoiding sleeping in contact lenses unless prescribed by your eye care professional.
6. *Avoid Allergens or Irritants:* If you are prone to allergic conjunctivitis, identifying and avoiding the triggers that cause your allergies can help prevent recurrent episodes.
7. *Practice Eye Safety:* Taking precautions to protect your eyes from injury can help prevent infectious conjunctivitis caused by physical irritants. When working in potentially hazardous environments or participating in activities with a risk of eye injury, wear protective eyewear, such as safety goggles or glasses [49].
8. *Maintain a Healthy Lifestyle:* by Eating a Balanced Diet, Exercising Frequently, Managing Stress Levels, and Getting Enough Sleep to Support Optimal Immune Function.
9. *Vaccinations:* In some cases, vaccinations can provide protection against certain types of conjunctivitis. For example, vaccination against bacterial infections such as Haemophilus influenza or Streptococcus pneumonia may be recommended, especially for children.
10. *Seek Early Treatments for Eye Infections:* Get medical help as soon as possible if you think you may have conjunctivitis or another type of eye infection. It is crucial to see a medical practitioner for a precise diagnosis and recommended course of treatment if you suspect you have conjunctivitis or if you are having symptoms yourself [50].

### **CONCLUSION**

In this above information we have explored a Wide vary of elements related to this common ocular condition. Our analysis encompassed the Epidemiology, etiology, scientific presentation, diagnostic methods, cure modalities, and latest advancements in understanding Conjunctivitis it remains a normal circumstance globally, with a giant have an effect on public health due to its contagious nature and the

attainable for Outbreaks. Viral or viral ocular infections constitute a significant proportion of the global burden of disease. We discovered a vast spectrum of etiological sellers accountable for conjunctivitis, Such as viruses, bacteria, allergens, and irritants. Understanding the unique causative elements is crucial for correct prognosis and targeted treatment. The advent of molecular diagnostics, Such as PCR, has extensively expanded the accuracy of conjunctivitis diagnosis, allowing for Speedy identification of pathogens and informed cure decisions. Treatment techniques have evolved, with a shift towards evidence-based management. Antiviral and antibacterial Treatments are often used; however supportive care and hygiene measures continue to be vital in contamination control.

Preventive measures, such as vaccination for viral conjunctivitis and promoting hygiene Practices, are integral in reducing the incidence and transmission of conjunctivitis, especially in outbreak settings. Empowering patients with expertise about conjunctivitis, its modes of Transmission, and fabulous precautions is vital in preventing its spread. Now a days the conjunctivitis are rare problem in human being and the people who are suffering from conjunctivitis the information is very helpful for to cure a disease.

## REFERENCES

1. Shekhawat NS, Shtein RM, Blachley TS, Stein JD. Antibiotic prescription fills for acute conjunctivitis among Enrollees in a large United States managed care network. *Ophthalmology* 2017; 124:1099–1107.
2. Smith AF, Waycaster C. Estimate of the direct and indirect Annual cost of bacterial conjunctivitis in the United States. *BMC Ophthalmol* 2009;9:13.
3. Kaufman HE. Adenovirus advances: new Diagnostic and therapeutic options. *Curr Opin Ophthalmol*. 2011; 22(4):290-293.
4. Alfonso SA, Fawley JD, Alexa Lu X. Conjunctivitis. *Prim Care*. 2015 Sep; 42(3):325-45.
5. Azari AA, Barney NP. Conjunctivitis: a systematic review of diagnosis and treatment. *JAMA*. 2013 Oct 23; 310(16):1721-9.
6. Høvdig G. Acute bacterial conjunctivitis. *Acta Ophthalmol*. 2008 Feb; 86(1):5-17.
7. Shields T, Sloane PD. A comparison of eye problems in primary care and ophthalmology practices. *Fam Med*. 1991 Sep-Oct; 23(7):544-6.
8. Ryder EC, Benson S. Conjunctivitis. In: *Stat Pearls*. Treasure Island (FL): Stat Pearls Publishing LLC; 2020.
9. Narayana S, McGee S. Bedside diagnosis of the 'Red Eye': a systematic review. *Am J Med* 2015; 128:1220–1224.e1221?
10. Everitt H, Little P. How do GPs diagnose and manage acute infective conjunctivitis? A GP survey. *Fam Pract* 2002; 19:658–660.
11. O'Callaghan RJ. The Pathogenesis of Staphylococcus aureus Eye Infections. *Pathogens*. 2018 Jan 10;7(1)
12. Chu WK, Choi HL, Bhat AK, Jhanji V. Pterygium: new insights. *Eye (Lond)*. 2020 Jun; 34(6):1047-1050.
13. Leung AKC, Hon KL, Wong AHC, Wong AS. Bacterial Conjunctivitis in Childhood: Etiology, Clinical Manifestations, Diagnosis, and Management. *Recent Pat Inflamm Allergy Drug Discov*. 2018; 12(2):120-127.
14. Azari AA, Arabi A. Conjunctivitis: A Systematic Review. *J Ophthalmic Vis Res*. 2020 Jul-Sep; 15(3):372-395.
15. Bielory L, Meltzer EO, Nichols KK, Melton R, Thomas RK, Bartlett JD. An algorithm for the management of allergic conjunctivitis. *Allergy Asthma Proc*. 2013 Sep-Oct;34(5):408-20.
16. Frary J, Petersen PT, Pareek M. Hutchinson's sign of ophthalmic zoster. *Clin Case Rep*. 2020 Jan; 8(1):219-220.
17. Leibowitz HM. The red eye. *N Engl J Med*. 2000 Aug 03; 343(5):345-51.
18. Mahmood AR, Narang AT. Diagnosis and management of the acute red eye. *Emerg Med Clin North Am*. 2008 Feb; 26(1):35-55, vi.

19. Puri LR, Shrestha GB, Shah DN, Chaudhary M, Thakur A. Ocular manifestations in herpes zoster ophthalmic us. *Nepal J Ophthalmol*. 2011Jul-Dec; 3(2):165-71.
20. Liesegang TJ. Herpes zoster ophthalmic us natural history, risk factors, clinical presentation, and morbidity. *Ophthalmology*. 2008 Feb; 115(2 Suppl):S3-12.
21. Stenson S, Newman R, Fedukowicz H. Laboratory Studies in acute conjunctivitis. *Arch Ophthalmology*1982; 100:1275–1277.
22. Fitch CP, Rapoza PA, Owens S, Murillo-Lopez F, JohnsonRA, Quinn TC, et al. Epidemiology and diagnosis of acute Conjunctivitis at an inner-city hospital. *Ophthalmology* 1989;96:1215-1220
23. Newman H, Gooding C. Viral ocular manifestations: a broad overview. *Rev Med Virol* 2013; 23:281–294.
24. Lim KH, Yin-Murphy M. Epidemic conjunctivitis in Singapore in 1970 and 1971. *Singapore Med J* 1973; 14:86–89.
25. Kono R, Sasagawa A, Miyamura K, Tajiri E. Serologic Characterization and sero-epidemiologic studies on acute Haemorrhagic conjunctivitis (AHC) virus. *Am J Epidemiol* 1975; 101:444–457.
26. Zhang L, Zhao N, Huang X, Jin X, Geng X, Chan T-C, et al. Molecular epidemiology of acute hemorrhagicConjunctivitis caused by coxsackie a type 24 variant in China, 2004-2014. *Sci Rep* 2017; 7:45202.
27. Høvdning G. Acute bacterial conjunctivitis. *ActaOphthalmol*. 2008; 86(1):5-17.
28. Mannis MJ, Plotnik RD. Bacterial conjunctivitis. In: Tasman W, Jaeger EA, eds. *DuanesOphthalmology on CD-ROM*. Lippincott Williams &Wilkins; 2006.
29. Epling J, Smucny J. Bacterial conjunctivitis. *ClinEvid*. 2005; 2(14):756-761.
30. Disorders of the conjunctiva and limbus. In: Yannof J, Duker JS, eds. *Ophthalmology*. 2<sup>nd</sup> ed. Spain: Mosby; 2004:397-412.
31. Bielory BP, O'Brien TP, and Bielory L. Management Of seasonal allergic conjunctivitis: guide to therapy. *Acta Ophthalmol*. 2012; 90(5):399-407.
32. Baudouin C, Pisella PJ, Fillacier K, et al. Ocular surface inflammatory changes induced by topical antiglaucomaDrugs: human and animal studies. *Ophthalmology*1999; 106:556–563.
33. Baudouin C, Labbe A, Liang H, Pauly A, Brignole-Baudouin F. Preservatives in eye drops: the good, the bad And the ugly. *Prog Retin Eye Res* 2010; 29:312–334.
34. Avery RK, Baker AS. *Albert and Jakobiec's Principle and Practice of Ophthalmology*. 3<sup>rd</sup> ed Saunders Elsevier; Philadelphia, PA: 2008. Chlamydial disease; pp. 4791–4801.
35. Tripathi KD. 2000. *Essentials of Medical Pharmacology*, Fourth edition; Jaypee Brothers Medical Publishers Ltd, New Delhi.
36. Tuomela R. 1987. Chapter 4- Science, Protoscience, and Pseudoscience; In Pitt JC, Marcello P, *Rational Changes in Science: Essays on Scientific Reasoning*, Boston Studies in the Philosophy of Science (Springer), pp. 83–101.
37. Varsney RL. 2000. *Marketing Management*, 2<sup>nd</sup> edition; Dr. S.L. Gupta Sultan Chand and Sons, New Delhi.
38. Wells JC. 2009. *Longman Pronunciation Dictionary*, London: Pearson Longman. Bio-social Issues in Health pp. 129 by Anil Kishore Sinha.
39. Narayana S, McGee S. Bedside diagnosis of the 'Red Eye': A systematic review. *Am J Med* 2015; 128:1220–1224.e1221
40. Wilson-Holt N, Dart JK. Thiomersal keratoconjunctivitis, Frequency, clinical spectrum and diagnosis. *Eye*1989; 3:581–587.
41. Fitch CP, Rapoza PA, Owens S, Murillo-Lopez F, JohnsonRA, Quinn TC, et al. Epidemiology and diagnosis of acute Conjunctivitis at an inner-city hospital. *Ophthalmology*1989; 96:1215–1220.
42. Cronau H, Kankanala RR, Mauger T. Diagnosis and Management of red eye in primary care. *Am Fam Phys*2010; 81:137–144.
43. Katusic D, Petricek I, Mandic Z, et al. Azithromycin vs doxycycline in the treatment of Inclusion conjunctivitis. *Am J Ophthalmol*.2003; 135(4):447-451.
44. Szaflik J, Szaflik JP, Kaminska A; Levofloxacin Bacterial Conjunctivitis Dosage Study Group. Clinical and microbiological efficacy of levofloxacin Administered three times a day for the treatment of Bacterial conjunctivitis. *Eur J Ophthalmol*.2009; 19(1):1-9.

- 
45. Owen CG, Shah A, Henshaw K, et al. Topical Treatments for seasonal allergic conjunctivitis: Systematic review and meta-analysis of efficacy and Effectiveness. *Br J Gen Pract.* 2004;54(503):
  46. Greiner JV, Minno G. A placebo-controlled Comparison of ketotifen fumarate and nedocromilSodium ophthalmic solutions for the prevention of ocular itching with the conjunctival allergen Challenge model. *Clin Ther.* 2003; 25(7):1988-2005.
  47. Workowski KA, Berman S; Centers for Disease Control and Prevention (CDC). Sexually transmitted Diseases treatment guidelines, 2010. *MMWR Recomm Rep.* 2010; 59(RR-12):1-110.
  48. Borkar DS, Acharya NR, Leong C, Lalitha P, Srinivasan M, Oldenburg CE, Cevallos V, Lietman TM, Evans DJ, Fleiszig SM. Cytotoxic clinical isolates of *Pseudomonas aeruginosa* identified during the Steroids for Corneal Ulcers Trial show elevated resistance to fluoroquinolones. *BMC Ophthalmol.* 2014 Apr 24; 14:54.
  49. Uo IC. adenoviral keratoconjunctivitis diagnosis, management, and prevention. *Curr ophthalmol Rep* 2019; 7:118-127.
  50. Monnerat N, Bossart W, Thiel MA. [Povidone-iodine for treatment of adenoviral conjunctivitis: an in vitro study]. *Klin Monbl Augenheilkd.* 2006 May; 223(5):349-52.